

Review

Characteristics of herpes zoster infection in patients with COVID-19: a systematic scoping review

Torrey Czech, MD and Yoshito Nishimura, MD, PhD, MPH 

Department of Medicine, John A. Burns
School of Medicine, University of Hawai'i,
Honolulu, Hawaii, USA

Correspondence

Yoshito Nishimura, MD, PHD, MPH
1356 Lusitana St., Room 715
Honolulu
Hawaii 96813
USA
E-mail: yoshiton@hawaii.edu

Conflict of interest: None.

Funding source: None.

doi: 10.1111/ijd.16221

Abstract

Background Although there is literature reporting correlations between varicella zoster virus (VZV) infections and COVID-19, insufficient evidence exists in this regard. This scoping review aims to identify the existing evidence regarding clinical characteristics of primary VZV infection or reactivation in COVID-19.

Methods Following the PRISMA Extension for Scoping Reviews, MEDLINE and EMBASE were searched for all peer-reviewed articles with relevant keywords including “Zoster,” “Herpes,” and “COVID-19” from their inception to November 20, 2021.

Results A total of 19 articles with three observational studies and 16 case reports or series were included. Primary VZV infections or reactivation were observed in 25 patients. Forty-eight percent of the patients had disseminated VZV infection. The median time of VZV-related rash after the onset of respiratory symptoms was 7.0 days (interquartile range: 0–18.8). Those with COVID-19 and primary VZV infection or reactivation had low lymphocyte counts with a median of $0.67 \times 10^3/\mu\text{l}$.

Conclusion This scoping review identified uncertainty and a lack of strong evidence to see the association between primary VZV infection or reactivation and COVID-19. However, those with COVID-19 may be more likely to have disseminated VZV, which poses an additional challenge from an infection prevention standpoint. Future studies are warranted to determine the association between primary VZV infection or reactivation and long-term consequences related to COVID-19.

Introduction

Coronavirus disease 2019 (COVID-19) is associated with severe respiratory illness; however, the spectrum of the clinical syndrome includes a high prevalence of cutaneous findings, with an estimated prevalence of up to 20.4%.^{1–3} A Spanish research team reported 375 cases of COVID-19 with cutaneous manifestations during the early period of the COVID-19 pandemic and divided them into categories of acral areas with vesicles or pustules (pseudo-chilblain), vesicular eruptions, urticarial lesions, maculopapular eruptions, and livedo or necrosis.⁴ Although the interaction between cutaneous changes and the COVID-19 disease burden is not fully understood, reporting COVID-19-related cutaneous manifestations is important for physicians given their possible correlations with unrecognized medical complications with COVID-19, especially in the inpatient setting.⁵

Among the cutaneous manifestations, varicella zoster (VZV) has attracted the attention of some researchers, with hypotheses that the reactivation of VZV might be associated with the severity of COVID-19, the initial symptoms of COVID-19, or could be a harbinger of future post-acute sequelae of COVID-19 (PASC).^{1,6–9} During the early period of the COVID-19 pandemic in 2020, some researchers hypothesized that VZV

reactivation in COVID-19 patients might have been associated with immunosuppression related to COVID-19. A number of case reports have been published reporting the herpesvirus infection in COVID-19 patients.

Despite the attention, there is insufficient evidence regarding the relationship between VZV and COVID-19. In this study, we summarized current evidence available regarding VZV in COVID-19 to identify the clinical characteristics and utility of the infections in COVID-19 patients with a systematic scoping review.

Materials and methods

Study design

We performed a systematic scoping review in accordance with the Preferred Reporting Items for Systematic Reviews and Meta-Analyses (PRISMA) extension for scoping reviews (PRISMA-ScR).^{10,11} Appendix S1 is the PRISMA-ScR checklist of the present study.

Search strategy

MEDLINE and EMBASE searches were conducted for all peer-reviewed articles from inception to November 20, 2021.

We employed no filters for study design and language. Additional relevant articles were screened with the reference lists of all articles that satisfied the eligibility criteria. The search strategy harbored relevant keywords, including “Herpes,” “Shingles,” and “COVID-19.” Two authors (TC and YN) conducted the search independently. See Appendix S2 for detailed search terms.

Eligibility criteria

The criteria for the inclusion of articles are as follows:

- 1 Peer-reviewed articles describing the relationship between VZV and COVID-19, or cases of primary VZV infection or reactivation in patients with laboratory-confirmed COVID-19.
- 2 Randomized controlled trials, case-control studies, cohort studies (prospective or retrospective), cross-sectional studies, and case series

The exclusion criteria included the following:

- 1 Qualitative studies, review articles, and commentaries
- 2 Conference abstracts
- 3 Diagnosis of COVID-19 made without confirmatory polymerase chain reaction testing

Study selection

TC and YN assessed selected articles for full-text assessment independently using EndNote 20 reference management software. Articles considered eligible were subsequently evaluated at full length.

Data extraction and definition

We used a standardized data collection form that followed the PRISMA and Cochrane Collaboration guidelines for systematic reviews to obtain the following information from each study: title, name of authors, year of publication, country of origin, study characteristics, target outcome, aims, study and comparative groups, key findings, and limitations. We also summarized data from included cases to identify clinical characteristics of primary VZV infection or reactivation in COVID-19. Disseminated VZV infection is defined as >3 dermatomes or ≥ 2 nonadjacent dermatomes or >20 skin lesions beyond the primary or adjacent dermatomes.¹²

Results

Search results and study selection

Figure 1 illustrates a PRISMA flow diagram that depicts the process of identification, screening, eligibility, and inclusion of

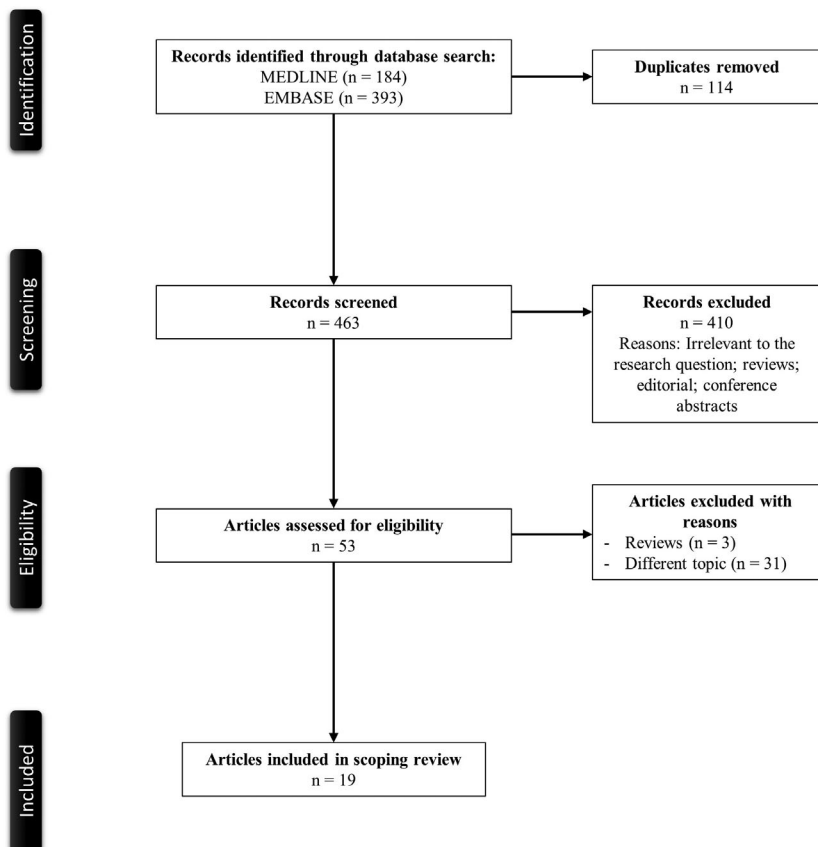


Figure 1 PRISMA flowchart of the search strategy

exclusion of the studies. The initial search of MEDLINE and EMBASE databases yielded 184 and 393 articles, respectively. One hundred and fourteen duplicate studies were removed, and 463 articles were screened based on their relevance and type of article. Four hundred and ten articles that were either review articles, editorials, or conference abstracts were excluded from the study, and 53 articles were then evaluated for full-text review for study inclusion per our eligibility criteria. Reviews, opinion articles, and articles with irrelevant topics were excluded. A total of 19 articles with three observational studies and 16 case reports or series were included in the review.^{6,13–30}

Description of included studies

Table 1 describes the main characteristics of three observational studies from the scoping review. Giavedoni et al. conducted a retrospective analysis of COVID-19 skin lesions in order to characterize the clinical patterns of the lesions. Among the included 58 patients, one had herpes zoster and two had varicella. The time from the beginning of respiratory symptoms to the onset of dermatologic findings was 14 days in two patients, and the one with varicella had skin lesions simultaneously with the respiratory symptoms.¹⁸ Katz et al. performed a retrospective case-control study to evaluate the incidence of herpes zoster in COVID-19 patients compared with those without COVID-19.²⁷ They found 16/889 (1.8%) had primary VZV infection or reactivation with COVID-19, compared with 4228/987,849 (0.43%) in those without COVID-19 based on International Classification of Diseases (10th edition). However, no details about individual patients were included. Matar et al. conducted a single-center retrospective observational study to see the incidence of cutaneous lesions in COVID-19 patients, which included eight herpetiform rashes including herpes reactivation (no details noted) among 759 COVID-19 patients.¹⁹

Review of included cases

Table 2 presents baseline demographics and clinical characteristics of patients with primary VZV infection or reactivation and COVID-19 ($n = 25$) with a slight female predominance (44.0% male and 52.0% female, one patient with unspecified sex). Rash was mainly found in the trunk (60.0%) or trigeminal areas (40.0%) with only a small number of patients with lesions on extremities (12.0%). The vesicular eruption was the most common type of rash, but 16.0% of the patients had necrotic lesions. The onset of the dermatologic manifestations varied, but with the median of 7.0 days (interquartile range [IQR]: 0–18.8) after the onset of respiratory symptoms. While only 40.0% of the included cases described the lymphocyte counts of the patients, patients had low lymphocyte counts with a median of $0.67 \times 10^3/\mu\text{l}$ (IQR: $0.51\text{--}1.55 \times 10^3/\mu\text{l}$).

Discussion

The present study is the first systematic scoping review and analysis of existing case reports and a series of HSV and VZV

cutaneous manifestations in those with COVID-19. Our results underscore that HSV reactivation occurs at various times in relation to COVID-19 without certain trends. Interestingly, we also found that 42.4% of the patients had disseminated disease.

The dermatologic manifestations of COVID-19 are variable with unclear underlying pathogenesis. Some have hypothesized that findings including mottling, livedo reticularis, petechiae, purpura, and chilblain might be associated with microthrombosis related to disseminated intravascular coagulation, acral ischemia, and thrombocytopenia.^{31–33} VZV reactivation is one of the skin manifestations, likely due to lymphopenia causing decreased cytotoxic T lymphocytes in COVID-19.³⁴ In primary VZV infection, VZV viremia can occur as early as 10 days, and the production cycle of VZV in a cell was noted to be around 9 hours.^{35,36} Thus, the timing of a viral replication cycle or viremia could still coincide with the onset of COVID-19 symptoms. VZV reactivation may be an epiphenomenon that reflects immune failure; however, given the considerable variability in the timing of the onset of rash, it is still unclear whether VZV reactivation may be associated with COVID-19 being a preceding phenomenon or a consequence of physical and psychological stress associated with the respiratory illness.

Interestingly, more than 40% of the included cases had disseminated VZV infection. VZV dissemination may occur as a primary infection, nearly exclusively in immunocompromised adults including those with age-related immunosenescence.^{37,38} While disseminated VZV infection is uncommon and typically seen in immunocompromised individuals, patients with COVID-19 had a high prevalence of the disseminated disease. It could be due to iatrogenic immunosuppression in COVID-19 patients with medications such as corticosteroids or effects of COVID-19 itself, which might be related to lymphopenia seen in severe COVID-19. Although it could be due to tissue infiltration or destruction of lymphocytes, the exact mechanism of the lymphopenia in COVID-19 has not been elucidated to date.³⁹ Future studies are warranted to see a relationship between the COVID-19-related lymphopenia and cellular immunity against viral infection or reactivation.

Patients with disseminated VZV infection should be placed on airborne and contact precautions until lesions are dry and crusted. While physicians tend to clear patients from isolation based solely on the duration of COVID-19, recognition of disseminated VZV infection is also crucial from an infection control standpoint.

Several limitations in the current study should be noted. First, reactivation of VZV is a clinical diagnosis. Thus, there may be either under- or overdiagnosis of VZV reactivation. Next, rash related to VZV reactivation could be asymptomatic or too mild to be noticed by clinicians, leading to selection bias that severe cases may be more likely to be reported. Third, VZV-related rash is common, with an incidence rate of 3.1–11.8 per 1000 person-years depending on the age group.³⁷ Thus, patients might have had VZV-related rash and COVID-19 within a close time period solely by coincidence. Also, included studies did not

Table 1 Main characteristics of the included observational studies in the scoping reviews

Author, Year, Country	Study type	Aim	Outcome	Population	Comparative groups	Detail of VZV infection	Key findings	Limitations
Giavedoni et al. 2020 Spain	Prospective cohort	To characterize clinical patterns of COVID-19-related skin lesions	Description of rash	Patients with COVID-19-associated skin lesions (n = 58)	N/A	<p>Papulovesicular eruptions on the trunk</p> <p>1 patient had herpes zoster</p> <p>2 patients had varicella</p>	<p>The time from the beginning of respiratory symptoms to the appearance of skin lesions; 14 days for HZ and 1 patient with chickenpox.</p> <p>The other patient with varicella had a rash at the same time with respiratory symptoms</p>	<p>Single-center study (an adult tertiary hospital) with a short inclusion period (4/1/2020 to 5/1/2020) leading to selection bias</p> <p>Skin biopsy not performed in all patients; subjective diagnosis</p> <p>Milder clinical presentations might not have been detected</p> <p>Data acquisition was done based on ICD 10 codes of those hospitalized in a single academic hospital from 10/2015 to 6/2020; diagnosis might not be accurate</p> <p>No detailed individual patient information</p>
Katz et al. 2021 USA	Retrospective case control	To evaluate the incidence and prevalence of HZ in COVID-19 patients	HSV and VZV infections	Patients with COVID-19 and HSV (n = 25) or VZV (n = 16) A total of 889 COVID-19 patients	Patients without COVID-19 but with HSV (n = 7625) or VZV (n = 4228) A total of 987,849 hospitalized patients	<p>The prevalence of HSV or VZV infections were determined based on ICD 10 codes</p>	<p>Prevalence of HSV-1 in COVID-19 group was 2.8% vs. 0.77% in those without COVID-19; OR 5.23 (p < 0.001).</p> <p>Prevalence of VZV in COVID-19 group was 1.8% vs. 0.43% in those without COVID-19; OR 5.26 (p < 0.001).</p>	<p>Smaller clinical presentations might not have been detected</p> <p>Data acquisition was done based on ICD 10 codes of those hospitalized in a single academic hospital from 10/2015 to 6/2020; diagnosis might not be accurate</p> <p>No detailed individual patient information</p>
Matar et al. 2020 France	Retrospective observation	To evaluate the incidence and prognosis of cutaneous lesions in COVID-19 patients	Description of rash	Herpetiform lesions (n = 8)	None	<p>None; 8 patients include herpes reactivation but without details</p>	<p>Rashes associated with COVID-19 were described as erythematous, maculopapular/morbiliform, urticarial/annular, vesicular/varicelliform, or petechial</p>	<p>Small sample sizes; less than 8 among 759 COVID-19 patients with herpes reactivation but no details</p> <p>When accounting for rashes, did not include detail of vesicular lesion to confirm HSV/VZV</p>

COVID-19, coronavirus disease 2019; HSV, herpes simplex virus, ICD, International Classification of Diseases VZV, varicella zoster virus.

Table 2 Clinical characteristics of the 25 patients from case reports and case series

	Prevalence (%) ^a	Median (IQR)
Age (years)	24/25 (96.0%)	62.0 (39.0–69.5)
Sex		
Male	11/25 (44.0)	
Female	13/25 (52.0)	
Unspecified	1/25 (4.0)	
Distribution of rash		
Trigeminal areas	10/25 (40.0)	
Trunk	15/25 (60.0)	
Extremities	3/25 (12.0)	
Unspecified	1/25 (4.0)	
Type of rash		
Necrotic	4/25 (16.0)	
Hemorrhagic	1/25 (4.0)	
Vesicular eruption	15/25 (60.0)	
Maculopapular	1/25 (4.0)	
Unspecified	4/25 (16.0)	
Disseminated	12/25 (48.0%)	
Onset of rash (days after COVID-19 diagnosis)	24/25 (96.0%)	7.0 (0–18.8)
Lymphocyte counts (10 ⁹ /μl)	10/25 (40.0%)	0.67 (0.51–1.55)

IQR, interquartile range.

^aPrevalence here is defined as the number of cases reported in the variable divided by the number of total cases.

specify whether their patients had either VZV reactivation or primary diseases. Another limitation is that there was a small number of observational studies with low-quality evidence and some cases with missing data, lowering the precision of the results.

Despite the limitation, our results suggest a possible correlation between VZV reactivation and COVID-19. However, given the increased incidence of disseminated VZV infection, clinicians need to be aware of the importance of skin examinations in COVID-19 patients. Future research areas related to VZV reactivation in COVID-19 may include the detailed analysis of the extent of cellular immunity in COVID-19 patients with a focus on VZV-specific cytotoxic T lymphocytes as well as prospective analysis of patients with a history of COVID-19 to see if there is an increased incidence of VZV reactivation as well as the association between PASC and VZV.

Authors' Contribution

TC conceived the study, searched the literature, and drafted the manuscript. YN searched the literature, assessed the quality of the studies, revised the manuscript, and supervised the study.

References

- 1 Recalcati S. Cutaneous manifestations in COVID-19: a first perspective. *J Eur Acad Dermatol Venereol* 2020; **34**: e212–e213.

- 2 Shinkai K, Bruckner AL. Dermatology and COVID-19. *JAMA* 2020; **324**: 1133–1134.
- 3 Yue H, Bai X, Wang J, et al. Clinical characteristics of coronavirus disease 2019 in Gansu province, China. *Ann Palliat Med* 2020; **9**: 1404–1412.
- 4 Galván Casas C, Català A, Carretero Hernández G, et al. Classification of the cutaneous manifestations of COVID-19: a rapid prospective nationwide consensus study in Spain with 375 cases. *Br J Dermatol* 2020; **183**: 71–77.
- 5 Do MH, Stewart CR, Harp J. Cutaneous manifestations of COVID-19 in the inpatient setting. *Dermatol Clin* 2021; **39**: 521–532.
- 6 Ferreira A, Romão TT, Macedo YS, et al. COVID-19 and herpes zoster co-infection presenting with trigeminal neuropathy. *Eur J Neurol* 2020; **27**: 1748–1750.
- 7 Maia CMF, Marques NP, de Lucena EH, et al. Increased number of herpes zoster cases in Brazil related to the COVID-19 pandemic. *Int J Infect Dis* 2021; **104**: 732–733.
- 8 Meyer A, Buetti N, Houhou-Fidouh N, et al. HSV-1 reactivation is associated with an increased risk of mortality and pneumonia in critically ill COVID-19 patients. *Crit Care* 2021; **25**: 417.
- 9 Proal AD, VanElzakker MB. Long COVID or post-acute sequelae of COVID-19 (PASC): An overview of biological factors that may contribute to persistent symptoms. *Front Microbiol* 2021; **12**: 698169.
- 10 McGowan J, Straus S, Moher D, et al. Reporting scoping reviews-PRISMA ScR extension. *J Clin Epidemiol* 2020; **123**: 177–179.
- 11 Tricco AC, Lillie E, Zarin W, et al. PRISMA extension for scoping reviews (PRISMA-ScR): Checklist and explanation. *Ann Intern Med* 2018; **169**: 467–473.
- 12 Bollea-Garlatti ML, Bollea-Garlatti LA, Vacas AS, et al. Clinical characteristics and outcomes in a population with disseminated herpes zoster: a retrospective cohort study. *Actas Dermosifiliogr* 2017; **108**: 145–152.
- 13 Ayaz CM, Dizman GT, Metan G, et al. Out-patient management of patients with COVID-19 on home isolation. *Infez Med* 2020; **28**: 351–356.
- 14 Brambilla L, Maronese CA, Tourlaki A, et al. Herpes zoster following COVID-19: a report of three cases. *Eur J Dermatol* 2020; **30**: 754–756.
- 15 Elsaie ML, Nada HA. Herpes zoster (shingles) complicating the course of COVID19 infection. *J Dermatolog Treat* 2022; **33**: 1123–1125.
- 16 Elsaie ML, Youssef EA, Nada HA. Herpes zoster may be a marker for COVID-19 infection during pregnancy. *Cutis* 2020; **106**: 318–320.
- 17 Elsaie ML, Youssef EA, Nada HA. Herpes zoster might be an indicator for latent COVID 19 infection. *Dermatol Ther* 2020; **33**: e13666.
- 18 Giavedoni P, Podlipnik S, Pericàs JM, et al. Skin manifestations in COVID-19: prevalence and relationship with disease severity. *J Clin Med* 2020; **9**: 1–12.
- 19 Matar S, Oulès B, Sohier P, et al. Cutaneous manifestations in SARS-CoV-2 infection (COVID-19): a French experience and a systematic review of the literature. *J Eur Acad Dermatol Venereol* 2020; **34**: e686–e689.
- 20 Pona A, Jiwani RA, Afriyie F, et al. Herpes zoster as a potential complication of coronavirus disease 2019. *Dermatol Ther* 2020; **33**: e13930.
- 21 Shors AR. Herpes zoster and severe acute herpetic neuralgia as a complication of COVID-19 infection. *JAAD Case Reports* 2020; **6**: 656–657.

- 22 Tartari F, Spadotto A, Zengarini C, *et al.* Herpes zoster in COVID-19-positive patients. *Int J Dermatol* 2020; **59**: 1028–1029.
- 23 Xu R, Zhou Y, Cai L, *et al.* Co-reactivation of the human herpesvirus alpha subfamily (herpes simplex virus-1 and varicella zoster virus) in a critically ill patient with COVID-19. *Br J Dermatol* 2020; **183**: 1145–1147.
- 24 Bhargava P, Singdia H, Mathur R, *et al.* Herpes zoster duplex Unilateralis as a manifestation of severe lymphopenia in COVID-19. *Eur J Pain* 2021; **25**: 508–509.
- 25 Desai HD, Sharma K, Patoliya JV, *et al.* A rare case of varicella-zoster virus reactivation following recovery from COVID-19. *Cureus* 2021; **13**: e12423.
- 26 Ghosh B, Gajjar RA, Modi VK, *et al.* A rare case of herpes zoster in an adult patient recovered from symptomatic reinfection of COVID-19. *Cureus* 2021; **13**: e16274.
- 27 Katz J, Yue S, Xue W. Herpes simplex and herpes zoster viruses in COVID-19 patients. *Ir J Med Sci* 2021: 1–5. <https://doi.org/10.1007/s11845-021-02714-z>
- 28 Loh J, Tham SM, Tambyah PA, *et al.* Range of varicella zoster co-infections with covid-19, Singapore. *Infect Chemother* 2021; **53**: 391–394.
- 29 Maldonado MD, Romero-Aibar J, Pérez-San-Gregorio MA. COVID-19 pandemic as a risk factor for the reactivation of herpesviruses. *Epidemiol Infect* 2021; **149**: e145.
- 30 Voisin O, Deluca N, Mahé A, *et al.* Disseminated herpes zoster during COVID-19. *Infect Dis Clin Pract (Baltim Md)* 2021; **29**: e109–e110.
- 31 Alramthan A, Aldaraji W. Two cases of COVID-19 presenting with a clinical picture resembling chilblains: first report from the Middle East. *Clin Exp Dermatol* 2020; **45**: 746–748.
- 32 Bouaziz JD, Duong TA, Jachiet M, *et al.* Vascular skin symptoms in COVID-19: a French observational study. *J Eur Acad Dermatol Venereol* 2020; **34**: e451–e452.
- 33 Manalo IF, Smith MK, Cheeley J, *et al.* A dermatologic manifestation of COVID-19: transient livedo reticularis. *J Am Acad Dermatol* 2020; **83**: 700.
- 34 Seeßle J, Hippchen T, Schnitzler P, *et al.* High rate of HSV-1 reactivation in invasively ventilated COVID-19 patients: immunological findings. *PLoS One* 2021; **16**: e0254129.
- 35 Gershon AA, Breuer J, Cohen JL, *et al.* Varicella zoster virus infection. *Nat Rev Dis Primers* 2015; **1**: 15016.
- 36 Reichelt M, Brady J, Arvin AM. The replication cycle of varicella-zoster virus: Analysis of the kinetics of viral protein expression, genome synthesis, and virion assembly at the single-cell level. *J Virol* 2009; **83**: 3904–3918.
- 37 Yawn BP, Gildea D. The global epidemiology of herpes zoster. *Neuro* 2013; **81**: 928–930.
- 38 Gershon AA, Gershon MD, Breuer J, *et al.* Advances in the understanding of the pathogenesis and epidemiology of herpes zoster. *J Clin Virol* 2010; **48**(Suppl 1): S2–S7.
- 39 Fajgenbaum DC, June CH. Cytokine storm. *N Engl J Med* 2020; **383**: 2255–2273.

Supporting Information

Additional Supporting Information may be found in the online version of this article:

Appendix S1 Preferred reporting items for systematic reviews and meta-analyses extension for scoping reviews (PRISMA-ScR) checklist.

Appendix S2 Detailed search terms.